# Aripiprazole may be associated with QTc Prolongation


## Victoria Candy (Med Std) & Dr. Itoro Udo

C/o Dept of Psychiatry, Western University, London, Ontario &
St Joseph's Healthcare London, Ontario, Canada


## Introduction & Aim:

- Psychiatrists often consider Aripiprazole to be a cardiac neutral medication.
- Early Specific Product Characteristics (SPC) of Aripiprazole supported this popular notion.
- Hence it is often considered a suitable choice of antipsychotic in patients with cardiac diseases, especially involving cardiac rhythm.
- However, evolving evidence, mostly case reports, is beginning to show that Aripiprazole may also cause QTc prolongation.
- This has implications for the risks of Torsade de pointes and sudden cardiac death with Aripiprazole use
- Many practicing psychiatrists may not be aware of this update.

- **Aim:** This case serves to deliver an educational update for psychiatrists on the cardiac effects of Aripiprazole.

## Method:

A case report is presented, with consent; this involved the treatment of distressing symptoms of Schizophrenia with Aripiprazole as the only antipsychotic and only medication taken by an adult patient with limited previous cardiac history.
This case is evidence supporting the association of Aripiprazole with QTc prolongation.

**Structure of Aripiprazole**

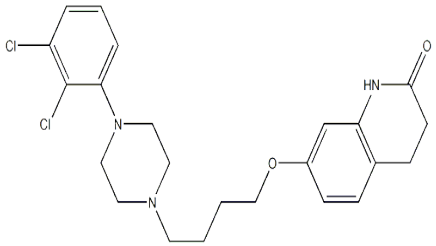


## Results:

- A known female patient in her 50s was admitted to hospital with suicidal ideation and parasuicidal behaviours.
- This presented an exacerbation of pre-existing psychosis.
- She had been treated for Paranoid Schizophrenia, presenting with auditory hallucinations and agitated behaviour.
- She was receiving IM Aripiprazole 400mg every 30 days. This was the **only** medication she had been taking.
- Long Acting Injectable (LAI) was indicated due to previous non-adherence to oral antipsychotics.
- On admission, she was found to have QTc of 518 ms.
- Aripiprazole was discontinued and she was treated with Oral Clonazepam.
- QTc reduced to her normal of 477 ms.
- Aripiprazole was reintroduced, orally at 2mg daily and then 5mg daily, at hospital discharge.
- Hallucinatory experiences and distress had abated at hospital discharge.
- This was only medication taken by patient following discharge
- At 2 weeks follow up, QTc had increased again, to 499 ms, prompting the permanent discontinuation of Aripiprazole.
- Review at 2 weeks showed a reduction of QTc to 490ms.
- Past Medical History was significant for intermittent prolongation of the PR interval and left bundle branch block. She did not have any symptoms.
- She did not have any significant history of electrolyte imbalances on or prior to admission.
- Referral to cardiology was made.

## Discussion:

Some antipsychotics increase the risk of prolongation of heart rate-corrected QT (QTc) and consequently Torsades de Pointes (TdP) and sudden cardiac death (SCD).

Psychiatrists need to be aware that Aripiprazole is now implicated with QTc prolongation.

Polcwiartek, Sneider, Graff, et al's systemic review and meta-analysis, 2015, found that TdP has been reported in two case reports and SCD was reported in one case report and one case series involving Aripiprazole. No clinical study had assessed Aripiprazole's cardiac safety in patients at high risk for torsade. The meta-analysis revealed that average QTc interval was decreased with Aripiprazole and QTc prolongation risk was lower compared with placebo and active controls. Aripiprazole was associated with weak to moderate torsadogenicity.

Maudsley's Prescribing Guidelines (13th edition) of 2018, has moved Aripiprazole from "no effect" to being of "low effect" group on QTc.

Those currently listed as being of no effect are **Brexiprazole, Cariprazine and Lurasidone**.

## Conclusion:

- The comprehensive cardiac evaluation of patients placed on antipsychotics continue to be of paramount importance.
- Earlier notions of the cardiac neutrality of Aripiprazole is being dispelled by evolving evidence.
- Pharmacovigilance is needed


**Acknowledgements:** Mental Health Library, Parkwood Institute, London & Oxford ACT Team, Woodstock, Ontario. Both of St. Joseph's Healthcare London, Ontario.


Reference available on request: **Itoro.Udo@sjhc.london. on. ca** @Udoatliaison